

Case Study for Non-Ablative Treatment of Acne Scars

Prepared by: Gaetano Zanelli, M.D.

Date: April 8, 2011

Disclaimer: The opinions expressed herein are those of the author(s), not necessarily those of Palomar Medical Technologies, Inc. ("Palomar"). Palomar and the author(s) assume no liability or responsibility for the contents of this publication. It is provided as a convenience only and is not intended to replace sound judgment or serve as the standard of care. Palomar's suggested guidelines are set forth in the operator's manuals and clinical treatment guides for Palomar products. Ultimately, a practitioner is solely responsible for the care of a particular client in light of all circumstances presented by the client, the diagnostic and treatment options at hand, and the available resources.

Profile

Case Study for Non-Ablative Treatment of Acne Scars By: Gaetano Zanelli, M.D.	
Physician name	Gaetano Zanelli, M.D.
Address	45 Castro St., Suite 215
City, state, ZIP Code	San Francisco, CA 94114
Phone number	415-487-1846
Web site address	Zskincenter.com
	
Contact name	Gaetano Zanelli
Title	M.D.
Phone number	415-487-1846
E-mail address	zsskincenter@gmail.com

Disclaimer: The opinions expressed herein are those of the author(s), not necessarily those of Palomar Medical Technologies, Inc. ("Palomar"). Palomar and the author(s) assume no liability or responsibility for the contents of this publication. It is provided as a convenience only and is not intended to replace sound judgment or serve as the standard of care. Palomar's suggested guidelines are set forth in the operator's manuals and clinical treatment guides for Palomar products. Ultimately, a practitioner is solely responsible for the care of a particular client in light of all circumstances presented by the client, the diagnostic and treatment options at hand, and the available resources.

Introduction:

34 year old Asian woman with Type III skin presented with moderate to severe acne and acne scarring. 5 years before laser treatments, she was treated with isotretinoin 1 mg/kg for 5 months, with general resolution of the acne breakouts.

Discussion:

Treatment plan was to utilize the Lux1540™ non-ablative fractional laser to improve acne scars.

Treatment with StarLux® 500 System and Lux 1540™ Handpiece:

Treatment sessions:

- 1st treatment: 50 mJ/15 ms, 10 mm tip, 3 passes
- 2nd treatment 5 weeks later: 50 mJ/15 ms, 10 mm tip, 3 passes
- 3rd treatment 5 weeks later: 50 mJ/15 ms, 10 mm tip, 3 passes
- 4th treatment 5 weeks later: 50 mJ/15 ms, 10 mm tip, 3 passes
- 5th treatment 5 weeks later: 50 mJ/15 ms, 10 mm tip, 3 passes
- 6th treatment 6 weeks later: 50 mJ/15 ms, 10 mm tip, 4 passes

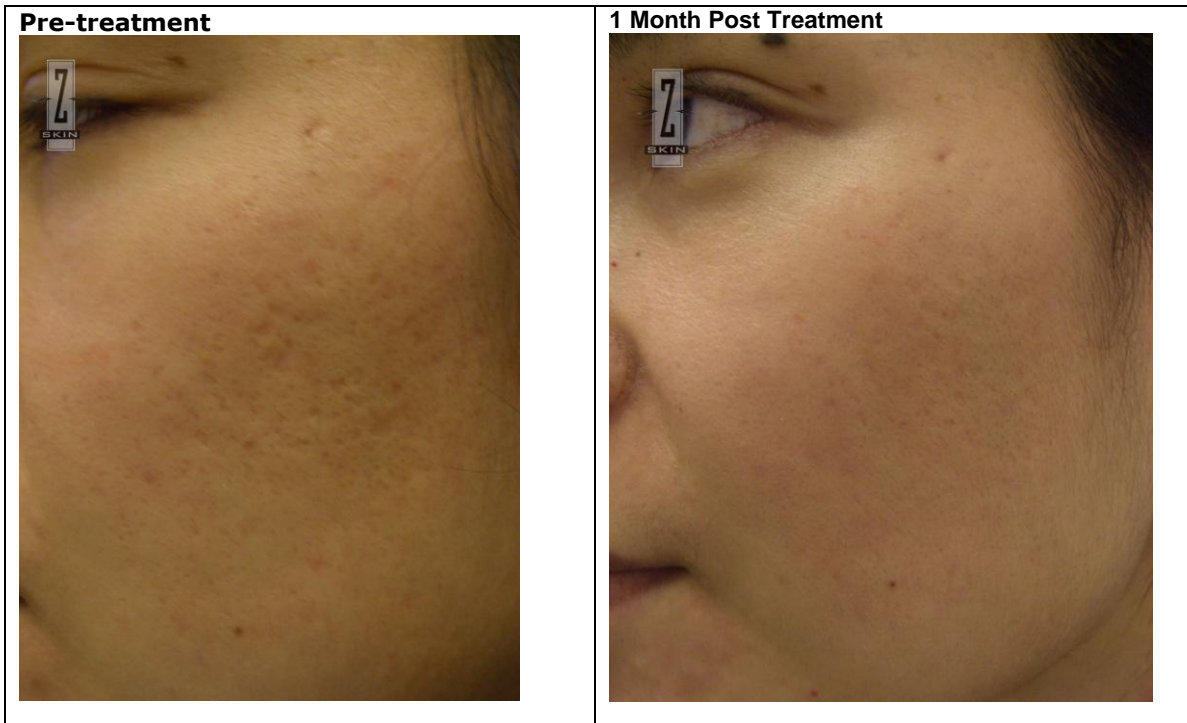
Conclusion:

Patient had some transient hyperpigmentation after each treatment which resolved with topical retinoid and 4% hydroquinone. Marked improvement of acne scars and skin texture after six treatments.

Physician Quote: "I was very impressed with the notable improvement and pleased that the patient was satisfied."

Patient Quote: "I am very happy with the results."

StarLux is a registered trademark and Lux1540 is a trademark of Palomar Medical Technologies, Inc. (Burlington, MA)



Disclaimer: The opinions expressed herein are those of the author(s), not necessarily those of Palomar Medical Technologies, Inc. ("Palomar"). Palomar and the author(s) assume no liability or responsibility for the contents of this publication. It is provided as a convenience only and is not intended to replace sound judgment or serve as the standard of care. Palomar's suggested guidelines are set forth in the operator's manuals and clinical treatment guides for Palomar products. Ultimately, a practitioner is solely responsible for the care of a particular client in light of all circumstances presented by the client, the diagnostic and treatment options at hand, and the available resources.